



ISSN: 1608-9391
e-ISSN: 2664-2786

Received:25/10/2020
Accepted:31/12/2020

Overview on Epidemiology of Leishmaniasis in Iraq

*Haitham L. Al-Hayali

**Muntaha M. Al-Kattan

Department of Biology/ College of Science/ University of Mosul

*E-mail: haysbio68@uomosul.edu.iq

**E-mail: Muntsbio17@uomosul.edu.iq

ABSTRACT

Leishmaniasis continues to be a significant public health issue and socioeconomic obstacle in Iraq. The various species of leishmania are transmitted by the bite of sandflies belonging to genus phlebotomus, where high temperatures might prolong the breeding season for this fly species. The current review proved that the infection in the southern regions of Iraq is more than in the northern regions.

The incidence of leishmaniasis has increased and expanded to most Iraqi governorates, the reason may be due to the population growth, urbanization, pronounced poverty and lack of public health awareness. Furthermore, leishmaniasis is a zoonotic disease with a rodent, cats and dog's reservoir that poses a problem to human health. Leishmaniasis has spread in Iraq from the 1950s until now, additionally, wars forced migration of Iraqi people from their province to other places. All these have encouraged an increase in the infected rate with leishmaniasis in areas previously uninfected.

Keywords: leishmaniasis, epidemiology, governorates, Iraq.

INTRODUCTION

Leishmaniasis is a neglected tropical disease NTD. More than one billion people are at risk of contracting this disease in all continents. This disease may debilitate many people and prevent them from living a decent life and preventing productive work properly (Wamai *et al.*, 2020).

The physicians Leishman and Donovan were the first to describe the visceral leishmaniasis pathogen at 1903, it is found in stained smears from the spleen of infected patients who showed symptoms of a disease similar to malaria, and later they called it *Leishmania donovani* (Bessat and El Shanat, 2013).

Leishmaniasis is a protozoan disease occurring in most tropical and subtropical countries worldwide and acquired through the bite of infected sand flies. The parasites causing leishmaniasis may live and multiply in humans, domestic or stray dogs, and rodents. Multiple strains of the parasite exist, each of which may result in different disease manifestations.

The current epidemiological statistics indicate that there are 12-15 million cases of leishmaniasis around the world, one to two million new cases are recorded annually. Visceral leishmaniasis is estimated in 500 thousand new cases annually and that 70 thousand of these injuries lead to death (Iddawela *et al.*, 2018).

Leishmania are sand fly-vector parasites that appear as intracellular amastigotes multiplies inside the phagolysosomes of mammalian and as extracellular flagellated promastigotes either in the culture or in the gut of the sand fly (Rahi *et al.*, 2013). Leishmaniasis is a complex disease caused by protozoan intracellular parasites, belonging to the genus *Leishmania*, order Kinetoplastida, family Trypanosomatidae. The infection transmitted through female Phlebotominae sand flies of the genus *Lutzomyia* in New World (America) further to *Phlebotomus* in the Old World (Asia, Africa and Europe) (Garrido-Jareno *et al.*, 2020).

Leishmaniasis is becoming more common worldwide because of urbanization and vector distribution. Recently, some studies discussed the crucial role of traveling between endemic and non-endemic areas and the possibility of production of new *Leishmania* hybrid (Sabzevari *et al.*, 2020).

Currently, the World Health Organization (WHO) recognizes leishmaniasis amongst the nine most important tropical and subtropical diseases occurring in all continents: Africa, Americas, Asia, and Europe (Torres-Guerrero *et al.*, 2017). The disease transmission cycle for this group is very complex due to the many species of *Leishmania* parasite. Circulating in different types of mammals by the bite of Phlebotomies. Humans are an incidental host and become infected when bitten by a female vector in searching for a blood (Ovalle-Bracho *et al.*, 2019).

The aims of the study are to determine the epidemiology and prevalence of leishmaniasis in the different governorates of Iraq.

Morphology

Leishmania can be distinguished for two phases: one of them the promastigote, which is present in the sand fly and the second the amastigote, which is present within the vertebral host (Sunter and Gull, 2017).

The Promastigote

It is located inside the gastrointestinal tract of the insect sand fly and in the culture media. Promastigotes is an extracellular and motile form. Considerably thin elongate cells, fusiform or lance-like in shape and ranging from 1.5-3.5 μm in width and 5-20 μm in length. Containing a long flagellum projected externally at the anterior end. The nucleus lies in the middle, in front of it are the kinetoplast and the basal body.

The Amastigote

In the amastigote form, the parasite resides in the cells of reticulo-endothelial system of vertebrates such as spleen, liver, bone marrow and lymph nodes. Its shape is oval, non-flattened and non-motile, measuring 1-3 μm in width and 3-8 μm in length. The flagellum being devoid and ineffective. The short flagellum does not project out and it embedded at the anterior end. The cytoplasm contains mitochondria, vacuoles and volutin granules. The kinetoplast consists of para basal body and blepharoplasty, which are connected by one or more fibrils.

Leishmaniasis Types

According to the clinical signs and the different tissues affected, the disease appears in four forms.

Cutaneous Leishmaniasis

Leishmania tropica and *Leishmania major* causes the skin infection, the disease often appears on the skin only and distinguished by the presence of one or several pustules depending on the leishmania species. Usually, this type is accompanied by the presence of ulcers, nodules and secondary infections with bacteria. The lesions appear as an erythematous papule at the site of sand fly bite and evolution over two to eight weeks, the papule increases in size to become larger nodules that eventually ulcerate and crusts over. The infection in this type is painless except of those with secondary bacterial infection and usually accompanied by self-healing in two to eighteen months. Lesions are often itchy and may have a wart-like hyperkeratotic appearance, leaving a permanent disfiguring and scars (Scott and Novais, 2016; Burza *et al.*, 2018).

Diffuse Cutaneous Leishmaniasis

The disease is a rare formula of skin infection, especially with *Leishmania amazonensis*. The pimples are not ulcerated but widely spread on the skin and may cause damage to the deep layers. The infection is not curable and lasts for a long time. Additionally, the infection may occur through the growth or development of new scarring or pustules around the skin edges of the newly healed pimples, which are often caused by *Leishmania tropica*, *Leishmania braziliensis* and patients require multiple courses of anti-parasitic therapy (Velez *et al.*, 2015; Freitas *et al.*, 2018).

Mucocutaneous Leishmaniasis

This type called also Espundia; devastating lesions involved nasopharyngeal mucosa with including the nasal septum, lips, and palate. About 90 % of cases shown a previous scar of cutaneous leishmaniasis (Cincura *et al.*, 2017). The disease is frequently chronic with a progressive destructive, disfiguring mid facial lesions leading to extensive mutilation. Respiratory tract invasion and secondary bacterial infection might lead to patient's demise. Being a potentially life-threatening disease, it requires immediate and early diagnosis, treatment and sometimes seen in immunocompromised individuals (Falcao *et al.*, 2020). It is usually found in Latin America, caused by *Leishmania braziliensis*, *Leishmania panamensis* and *Leishmania guyanensis* (Sachdeva and Sharma, 2016).

Visceral leishmaniasis

Leishmania donovani the major diseases pathogen and humans are the main reservoir. In addition to cause by *Leishmania infantum*, *Leishmania chgasi*, *Leishmania archibaladi*. The transmission can be anthroponotic or zoonotic. It known as kala-azar or black fever. It causes visceral disease, irregular fever, splenomegaly, hepatomegaly, thrombocytopenia, hyper-gammaglobulinemia, weight loss and pancytopenia. The fever characteristically shows a double rise in 24 hours with spikes of fever and afebrile intervals in between. This type of leishmaniasis is mostly destructive and fatal forms. The infection is ranging from asymptomatic to fulminant life-threatening disease. The disease may appear with an insidious or acute onset, but the

typical presentation is that of wasted, thin, cachectic manifestation with prominent abdominal distention due to hepatosplenomegaly. Jaundice considered a bad prognostic sign. The incubation period extends from two weeks to eight months (Zacarias *et al.*, 2017).

The moderate infections usually self-heals and often if untreated is fatal, secondary bacterial infection usually causes the mortality additionally to immunosuppression, hemorrhage and severe anemia (Khan *et al.*, 2015).

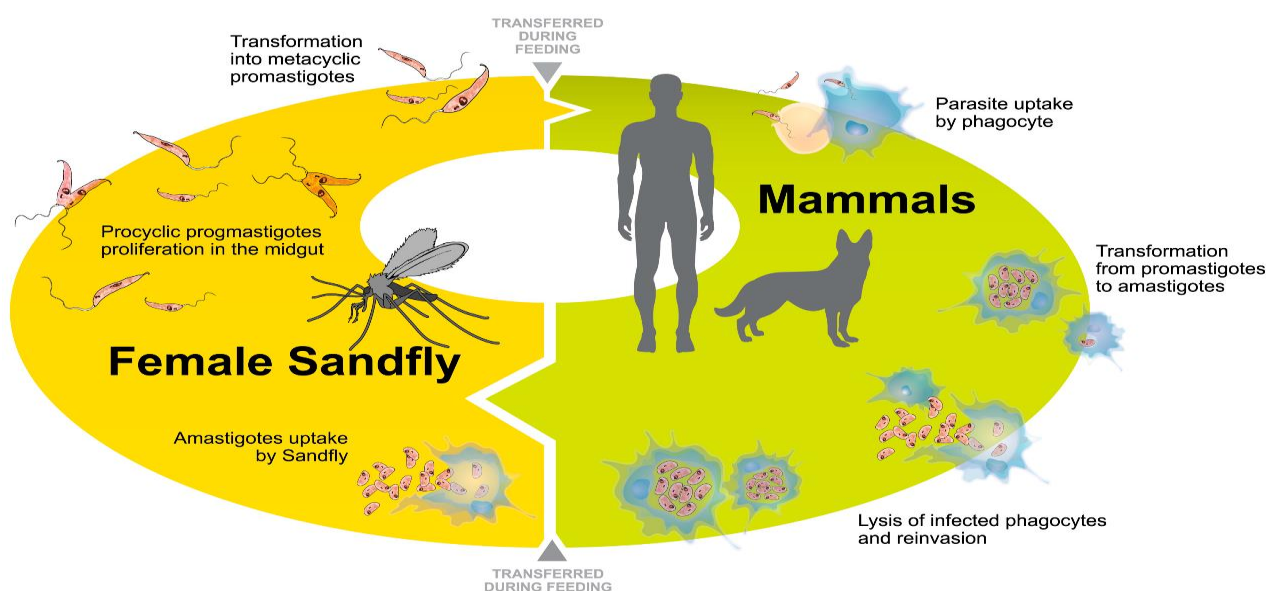
In some cases, Post kala-azar Dermal Leishmaniasis (PKDL) a skin condition that occurs after treatment of visceral leishmaniasis due to *Leishmania donovani*. The disease characterized by patches of pustules or a nodule-like rash, especially around the mouth. PKDL generally seen in Africa and India as a late complication of visceral to *Leishmania donovani* and infrequently *Leishmania infantum* (Zijlstra, 2016).

PKDL develops after 6 months and occasionally more than 5 years next the incidence of previous visceral, about 15% of cases do not show the prior kala-azar infection. It can diagnosis via slit-skin smears, culture or polymerase chain reaction. The clinical appearance is papular, macular or nodular lesions (Gedda *et al.*, 2020).

Life Cycle

The parasite's life cycle begins when the female sandflies gain infection during blood meal, whether human or animal host. The parasite develops over 4-25 days inside the vector transforming to a promastigote form where they multiply by binary fission in the mid gut and moving towards the pharynx. The infection will pass within a few days after ingestion when there is severe pharyngitis, so the promastigotes will be regurgitated via a bite to the host while feeding on the blood (Jamal *et al.*, 2020).

When sandflies feeding on the blood, the macrophage immediately defends and devours the invading body by the phagocytosis process, thus enter these organelles. The organisms lose the flagella, amastigotes are formed and continue multiplying until the cells of infected host get filled with the organisms then rupture releasing free amastigotes which invade new cells, thus the vicious cycle of *Leishmania* infection were continuing (Kaye and Scott, 2011). Some of amastigotes may enter the circulatory system and spread to the viscera leading to a visceral infection (Liu and Uzonna, 2012).



Life cycle of leishmania parasites (Veras and de Menezes, 2016)

Leishmaniasis in Iraq

Iraq is considered as the endemic area of leishmaniasis where both forms of the disease, cutaneous (Baghdad boil) and visceral (Kala-azar) found. Leishmaniasis is widespread in Iraqi governorates; the first cases were recorded in Mosul and Baghdad cities (Taj-Eldin and Alousi, 1954). As for (Sukker, 1986) he mentioned that middle of Iraq is infested with kala azar, were recorded 12038 cases of this disease during the years 1971-1984 and most of them in children especially in rural areas. While (Bray and Rahim, 1969; El-Yazachi, 1975) found that northern of Iraq is one of the areas affected with cutaneous leishmaniasis especially in Mosul.

In the year 2001, the World Health Organization stated that there were 10.9 cases of visceral leishmaniasis per 100,000 people distributed over governorates of Baghdad, Dhiqar, Muthanna, Maysan and Basra (WHO, 2004). The authors (Al-Hussaini *et al.*, 2017) showed that the central health laboratories in Baghdad identified 14502 cases infected with Kala-azar by indirect fluorescent antibody test (IFAT) from sixteen Provinces in Iraq in 2002. It seems that Wasit Province had the highest percentage of infections, and then it follows by Diala, Babylon and Baghdad. Additionally (Peter *et al.*, 2004) indicated that there were 310 cases of cutaneous and visceral leishmaniasis in the American soldiers coming from Iraq after the war. According to the report submitted by the health care department in Basra governorate, there are 608 cases of leishmaniasis, and 210 of them are in Qurna (Jafer, 2005). While (Jassim *et al.*, 2006) they confirmed that 877 cases of visceral infection in some cities of Dhiqar governorate during the year 2003 compared with 573 cases during the years from 1999 to 2002.

The annual number of reported cases with visceral leishmaniasis in Iraq is over 1000 and according to the data obtained from the section of the endemic disease institute, the number of cases reported during the years 1971-1984 was 12038 and about 90% of them were from Baghdad and central governorates. During the last few years, there was an increase in southern governorates (Hashim *et al.*, 2007).

It has mentioned that the number of visceral leishmaniasis in Iraq estimated in about 1711 cases per year, while the reports of the World Health Organization indicate that the infections ranged between 3400-6800 during 2004-2008 (WHO, 2018).

The epidemiological study by (Rabeea, 2008) of Wasit city mentioned that 178 cases of leishmanial infection (Al-Samarai and Al-Obaidi, 2009) demonstrated that there were 107 cases of cutaneous leishmaniasis in the city of Hawija affiliated to Kirkuk governorate between October 2004 and April 2005. While the study of (Al-Ani *et al.*, 2012) indicate about 32 cases of visceral infection in the patients of Ramadi Hospital at Anbar governorate, and that 75% of cases are in children under two years.

It is worth noting (Qader *et al.*, 2009) elucidated that in Al-Qadessia province alone, the recorded total cases of cutaneous leishmaniasis were 618 from 2005-2007. At the year 2008, about 1049 cases of visceral leishmaniasis were reported and 90% of these cases reported in children. Most of cases reported from the eastern provinces of Diyala, Wasit, Misan and Basrah (Majeed *et al.*, 2013).

The study of (Al-Warid *et al.*, 2017) showed that Iraq recorded 7112 positive cases of cutaneous leishmaniasis between the years 2011-2013, by (2978) cases in 2011, (2486) in 2012 and (1648) in 2013. Whereas the report of (WHO, 2015) indicated that the country of Iraq is the highly endemic area with a nearly 1000-4999 new cases in 2013.

In epidemiological study of (Al-Samarai *et al.*, 2016) showed that there were 571 cases of cutaneous leishmaniasis diagnosed in three health centers in Kirkuk for the period from April 2015 until April 2016. (Hassan, 2018) elucidate that there were 58 infected patients of cutaneous leishmaniasis, 35 were male and 23 were female with ages of 4-56 years, the lesions were located on the face, arms and legs in the specimens were collected from Rizgary and Komary Hospitals in Erbil.

Furthermore, (Abdulla *et al.*, 2018) demonstrated that the data obtained from Kurdistan region health directorate detected that no cases of cutaneous leishmaniasis were recorded before 2010. The incidence of infection was zero in 2008. In 2010, were reported about 15 cases increasing to 34 in 2011 and then to 88 in 2014, while the number of cases in 2015 reached to about 228. In addition to 259 cases reported at the year 2017, more than (41%) of cases were from Maxmur region, whereas 8% were refugees and (21%) were internally displaced persons (IDPs).

On the other hand (Ali *et al.*, 2018) they indicate that different parts of Iraq are endemic with visceral and cutaneous leishmaniasis. Annually 1800 visceral cases recorded in Iraq and estimated nearly 4000-5000 cases in recent years. Previous reports showed that cutaneous infection was indeed endemic in the northern parts of Iraq like Kirkuk, Salah-Eldin, Diyala, Missan and Wasit. Thousands of cutaneous cases also recorded from Americans armies in Iraq after war. Additionally, to collected about 700 cases of cutaneous leishmaniasis from eight Iraqi provinces as follows: Salah-Edin 76, Diyala 78, Baghdad 80, Basrah 82, Thiqrar 91, Najaf 94, Wasit 99 and Diwaniyah 100. Whereas, (Al-Khayat *et al.*, 2018) they illustrate that 1264 cutaneous leishmaniasis cases were diagnosed during the period from January 2015 to January 2017 were recorded from Makhmur town is situated 67 kms South-west of Erbil.

Additionally (Hussein *et al.*, 2019) indicated that 1482 cases were recorded of cutaneous leishmaniasis over 12 months between September 2016 and November 2017 in Mosul City, Rabeea District. This number may attribute to the significant decline in health services post war as well the poor sanitary conditions of the city, that might lead to an increase in vector populations. Additionally, the internal displacement of people from endemic areas may have played a role in increasing the number of cases.

Other researchers confirmed that there are 60 patients with cutaneous leishmaniasis with an age range of 3-71 years collected from Al-Diwaniyah Teaching Hospital and the study has been showed that 35% of them single lesions and 65% multiple. According to site of lesions, facial lesions seen in 50% of patients, upper lesions encountered in 30% and lower limb lesions seen in 20% (Abdul-Reda, 2019).

The researchers (Al-Waaly and Shubber, 2020) demonstrate that among 4276 samples were collected from people who reviewed to Al-Diwaniyah teaching hospital having dermal infected there are 1489 confirmed cases of cutaneous leishmaniasis after diagnosed externally by a specialist during the year 2018. As well explained that the injuries distributed as 800 cases in males and 689 in females.

Disease Prevention and Control

Leishmaniasis requires a set of intervention strategies to prevent infection transmission because it occurs in a complex biological system including the human or animal host as well the parasite and the vector, as follows:

1. Early diagnosis and prompt treatment of the infection might effectively reduce the prevalence of disease and prevent disability or death. Currently, there are effective and safe medicines that can pick up as an anti-leishmanial, especially for visceral leishmaniasis, although they are difficult to use.
2. Vector control helps decrease or stop transmission disease by reducing the number of sand flies. Control methods include spraying of insecticides (house or space), use of fine-weave insecticide-treated bed nets, environmental management and personal protection.
3. Well and promptly monitoring the disease may help to conduct good management and behavior during epidemics and high mortality rates in cases under treatment.
4. Controlling reservoir hosts can be very effective method mainly in situation of zoonotic transmission.

CONCLUSIONS

The cutaneous and visceral leishmaniasis is experiencing a noticeable increase in proliferation in different regions of Iraq and the results of the article indicate this reality. The study shows that leishmaniasis is more prevalent in the central and southern regions In Iraq than the northern regions, the reason may be due to high levels of humidity, which provides a good environment for the spread of the vector insect thus the disease spread. Finally, should be control on animal reservoir hosts, Effective behavior change by mobilizing and educating the community. Interventions vector-borne disease control programmers is critical.

REFERENCES

- Abdulla, Q.B.; Shabila, N.P.; Al-Hadithi, T.S. (2018). An Outbreak of Cutaneous Leishmaniasis in Erbil Governorate of Iraqi Kurdistan Region in 2015. *J. Infect. Dev. Ctries.*, **12**(8), 600-607.
- Abdul-Reda, F.S. (2019). Clinical Characteristics of Cutaneous Leishmaniasis in Al-Diwaniyah Province. *Ann. Trop. Med. Pub. Health*, **22**(12), 381-386.
- Al-Ani, Z.R.; Al-Hamwandi, A.M.; Al-Ma'aeni, A.A.; Al-Ta'aie, M.K. (2012). Kala-azar in Al-Anbar Governorate, Western Iraq. *Anbar Med. J.*, **10**(1), 41-49.
- Al-Hussaini, R.M.A.; Al-Tufaili, R.A.N.; Hussein, R.A. (2017). Molecular Study of Pediatric Visceral Leishmaniasis in Mid-Euphrates Area, Iraq. *Inter. J. Sci. Engineer. Res.*, **8**(8), 148-152.
- Ali, M. A.; Khamesipour, A.; Rahi, A. A.; Mohebbali, M.; Akhavan, A.; Firooz, A.; Keshavarz, H. V. (2018). Epidemiological study of cutaneous leishmaniasis in some Iraqi provinces. *J. Mens Health*, **14**(4), e18-e24.
- Al-Khayat, Z.A.Y.; Agha, N.F.S.; Alharmni, K.I.F.; Khudhur, Y.J. (2018). A Clinico-Epidemiological study on cutaneous leishmaniasis in Erbil, Iraq (2015-2017). *Int J. Res. Dermatol.*, **4**(1), 1-7.
- Al-Samarai, A.M.; Al-Obaidi, A.H.A.; Al-Jumaili, Z.K.; Jasim, M.M.; Qatal, S. (2016). Cutaneous leishmaniasis in Iraq: A continuing endemic disease. *J. Drug. Des. Res.*, **3**(1), 1024-1031.
- Al-Samarai, A.M.; Al-Obaidi, H.S. (2009). Cutaneous leishmaniasis in Iraq. *J. Inf. Develop. Count.*, **3**(2), 123-129.
- Al-Waaly, A.B.M.; Shubber, H.W.K. (2020). Epidemiological study of cutaneous leishmaniasis in Al-Diwaniyah Province, Iraq. *Eurasia. J. Biosci.*, **14**, 269-273.
- Al-Warid, H.S.; Al-Saqur, I.M.; Al-Tuwaijari, S.B.; AL Zadawi, K.A.M. (2017). The Distribution of cutaneous leishmaniasis in Iraq: Demographic and climate aspects. *Asian Biomed.*, **11**(3), 255-260.
- Bessat, M.; El Shanat, S. (2013). Leishmaniasis: epidemiology, control and future perspectives with Special emphasis on Egypt. *J. Trop. Dis.*, **3**(1), <http://dx.doi.org/10.4172/2329-891X.1000153>.
- Bray, R.S.; Rahim, G.A.F. (1969). Studies on the immunology and serology of leishmaniasis. VII. Serotypes of *L. tropica*. *Trans. Roy. Soc. Trop. Med. Hyg.*, **63**, 383-387.
- Burza, S.; Croft, S.L.; Boelaert, M. (2018). Leishmaniasis. *The Lancet*. **392**(10151), 951-970.
- Cincura, C.; de Lima, C.M.; Machado, P.R.L.; Oliveira-Filho, J.; Glesby, M.J.; Lessa, M.M.; Carvalho, E. M. (2017). Mucosal Leishmaniasis: A retrospective study of 327 cases from an endemic area of *Leishmania (Viannia) braziliensis*. *Am. J. Trop. Med. Hyg.*, **97**(3), 761-766.
- El-Yazachi, M. (1975). Research on 120 cases of *L. tropica*, epidemiology, incidence, clinical varieties, treatment and histopathology. *Iraqi. Med. J.*, **23**, 78-101.

- Falcao, G.G.; Lins-Kusterer, L.; Leite-Ribeiro, P.M.; Sarmiento, V.A. (2020). Orofacial manifestations of mucocutaneous leishmaniasis: A case series from Brazil [version 1; peer review: 1 not approved]. *Flo. Res.* **8**,756. <https://doi.org/10.12688/f1000research.19056.3>.
- Freites, C.O.; Gundacker, N.D.; Pascale, J.M.; Saldana, A.; Diaz-Suarez, R.; Jimenez, G.; Sosa, N.; Garcia, E.; Jimenez, A.; Suarez, J. A. (2018). First case of diffuse leishmaniasis associated with *Leishmania panamensis*. *OFID*, doi: 10.1093/ofid/ofy281.
- Garrido-Jareno, M.; Sahuquillo-Torralba, A.; Chouman-Arcas, R.; Castro-Hernandez, I.; Molina-Moreno, J.; Llavador-Ros, M.; Gomez-Ruiz, M.; Lopez-Hontangas, J.; Botella-Estrada, R.; Salavert-Lleti, M.; Peman-Garcia, J. (2020). Cutaneous and mucocutaneous leishmaniasis: Experience of a Mediterranean Hospital. *Parasit. Vect.* **13**, 24 <https://doi.org/10.1186/s13071-020-3901-1>.
- Gedda, M.R.; Singh, B.; Kumar, D.; Singh, A.K.; Madhukar, P.; Upadhyay, S.; Singh, O. P.; Sundar, S. (2020). Post kala-azar dermal leishmaniasis: A threat to elimination program. *PLOS Neg. Trop. Dis.*, <https://doi.org/10.1371/journal.pntd.0008221>.
- Hashim, J.M.; Galil, T.A.; Abdul-Kadim, S.H. (2007). Epidemiological and clinical study of visceral leishmaniasis in Najaf and Karbala Governorates. *Karbala J. Med.*, **1**(2), 124-130.
- Hassan, Z.I. (2018). Molecular characterization of cutaneous leishmaniasis isolated from human in Erbil Province-Kurdistan Region/ Iraq. *ZJPAS*, **30**(2), 76-85.
- Hussein, N.R.; Balatay, A.A.; Saleem, Z.S.M.; Hassan, S.M.; Assafi, M.S.; Sheikhan, R.S.; Amedi, F.R.; Hafzullah, S.S.; Hafzullah, M.S.; Xedr, A.M.; Zebary, M.T.; Aqrawi, H.A. (2019). A Clinical study of cutaneous leishmaniasis in a new focus in the Kurdistan Region, Iraq. *PLOS ONE* | <https://doi.org/10.1371/journal.pone.0217683>.
- Iddawela, D.; Vithana, S. M. P.; Atapattu, D.; Wijekoon, L. (2018). Clinical and epidemiological characteristics of cutaneous leishmaniasis in Sri Lanka. *BMC Infect. Dis.*, **18**, 108-117.
- Jafer, W.M. (2005) Report. CDC Surveillance Unit / Primary Health Care Department / Basrah.
- Jamal, Q.; Shah, A.; Rasheed, S. B.; Adnan, M. (2020). *In vitro* assessment and characterization of the growth and life cycle of *Leishmania tropica*. *Pakistan J. Zool.*, **52**(2): 447-455.
- Jassim, A.K.; Maktoof, R.; Ali, H.; Budosan, B.; Campbell, K. (2006). Visceral Leishmaniasis control in Thiqr Governorate, Iraq. *Eastern Med. Heal. J.*, **12** (2), 230-237.
- Kaye, P.; Scott, P. (2011). Leishmaniasis: Complexity at the Host-Pathogen Interface. *Nat. Rev. Microbiol.*, **9**, 604-615.
- Khan, S.; Khan, I.; Chauhanb, P. M. S. (2015). Antileishmanial chemotherapy: Present status and future perspectives. *Chem. Bio. Int.*, **5**(1), 1-28.
- Liu, D.; Uzonna, J. E. (2012). The early interaction of leishmania with macrophages and dendritic cells and its influence on the host immune response. *Front. Cell. Infect. Microbiol.*, **12**(83), 1-8.
- Majeed, B.; Sobel, J.; Nawar, A.; Badri, S.; Muslim, H. (2013). The persisting burden of visceral leishmaniasis in Iraq: Data of the national surveillance system, 1990-2009. *Epidem. Inf.* **141**(2), 443-446.
- Moura, C. R.; Costa, C. H.; Moura, R.; Braga, A. R.; Silva, V. C.; Costa, D. L. (2019). Cutaneous parasitism in patients with American visceral leishmaniasis in an endemic area. *Rev. Soc. Bras. Med. Trop.*, **53**, 1-6.
- Ovalle-Bracho, C.; Londono-Barbosa, D.; Salgado-Almario, J.; Gonzalez, C. (2019). Evaluating the spatial distribution of *Leishmania* parasites in Colombia from and human isolates (1999 to 2016). *PLOS ONE* <https://doi.org/10.1371/journal.pone.0214124>.
- Peter, J.; Weina, R.C.; Neafie, G.W.; Polhemus, M.; Aronson, N.E. (2004). Old world Leishmaniasis: An emerging infection among deployed US military and civilian workers. *CID*, **39**, 1674-1680.

- Qader, A.M.; Abood, M.K.; Bakir, T.Y. (2009). Identification of leishmania parasites in clinical samples obtained from cutaneous leishmaniasis patients using PCR technique in Iraq. *Iraqi J. Sci.*, **50**(1), 32-36.
- Rabeea, A.A. (2008). Epidemiological study of cutaneous Leishmaniasis in IRAQ-WASSIT. *Wasit J. Sci. Med.*, **1**(2), 13-22.
- Rahi, A.A.; Nsaif, S.; Hassoni, J.J.; Ali, M.A.; Hamza, H.A. (2013). Comparison of diagnostic methods in cutaneous Leishmaniasis in Iraq. *American J. BioSci.*, **1**(1), 1-5.
- Sabzevari, S.; Mohebali, M.; Hashemi, S. A. (2020). Cutaneous and visceral leishmaniasis: parasites, vectors and reservoir hosts in endemic foci of North Khorasan, Northeastern Iran-a Narrative Review. *J. Med. Microbiol. Infect. Dis.*, **8**(2), 40-44.
- Sachdeva, H.; Sharma, M. (2016). Clinical manifestations of leishmaniasis: A Review. *IJARSET*, **3**(12), 3093-3095.
- Scott, P.; Novais, F.O. (2016). Cutaneous Leishmaniasis: Immune responses in protection and pathogenesis. *Nat. Rev. Immunol.*, **16**(9), 581-592.
- Sukkar, F. (1986). Evaluation of visceral leishmaniasis control program. *Bull. End. Dis.*, **27**(1-4), 63-76.
- Sunter, J.; Gull, K. (2017). Shape, form, function and leishmania pathogenicity: from textbook descriptions to biological understanding. *Open Biol.*, **7**, 170165. <http://dx.doi.org/10.1098/rsob.170165>.
- Taj-Eldin, S.D.; Alousi, K. (1954). Kala-azar in Iraq. Report of Four Cases. *J. Fac. Med. Baghdad*, **18**(1-2), 15-19.
- Torres-Guerrero, E.; Quintanilla-Cedillo, M.R.; Ruiz-Esmenjaud, J.; Arenas, R. (2017). Leishmaniasis: a review [version 1; referees: 2 approved]. *Floo. Res.* **6** doi, 10.12688/f1000research.11120.1.
- Velez, I.D.; Jimenez, A.; Vasquez, D.; Robledo, S.M. (2015). Disseminated cutaneous leishmaniasis in Colombia: Report of 27 cases. *Case Rep. Dermatol.*, **7**, 275-286.
- Veras, P.S.T.; de Menezes, J.P.B. (2016). Using proteomics to understand how Leishmania parasites survive inside the host and establish infection. *Int. J. Mol. Sci.*, **17**, 1270-1285.
- Wamai, R.G.; Kahn, J.; McGloin, J.; Ziaggi, G. (2020). Visceral Leishmaniasis: A Global overview. *J. Glob. Heal. Sci.*, **2**(1), e3. <https://doi.org/10.35500/jghs.2020.2.e3>.
- WHO (2004). Communicable disease surveillance and report. 19 March 2003. <http://www.who.int/emc/diseases/leish/index>.
- WHO (2015) Leishmaniasis control program? Annual country report, world endemicity of cutaneous leishmaniasis. Available: [http://gamapserver.who.int/mapLibrary/Files/Maps/Leishmaniasis cutaneous leishmaniasis](http://gamapserver.who.int/mapLibrary/Files/Maps/Leishmaniasis%20cutaneous%20leishmaniasis).
- WHO (2018). Regional office for the Eastern Mediterranean. Summary report on the interregional meeting on leishmaniasis among neighboring endemic countries in the Eastern Mediterranean, African and European Regions: Amman, Jordan, 23-25 September. Cairo.
- Zacarias, D.A.; Rolao, N.; de Pinho, F.A.; Sene, I.; Silva, J.C.; Pereira, T.C.; Costa, D.L.; Costa, C.H.N. (2017). Causes and consequences of higher *Leishmania Infantum* burden in patients with Kala-Azar: A Study of 625 Patients. *Trop. Med. Intel. Health*, **22**(6), 679-687.
- Zijlstra, E.E. (2016). The Immunology of Post-Kala-Azar dermal leishmaniasis (PKDL). *Parasit. Vect.*, **9**, 464 doi 10.1186/s13071-016-1721-0.
-

نظرة عامة عن وبائية داء اللشمانيا في العراق

الملخص

لايزال داء اللشمانيا يمثل مشكلة صحية عامة كبيرة وعقبة اجتماعية اقتصادية في العراق. من المعروف أن المرض ينتقل عن طريق ناقل ذبابة الرمل وبالتالي فإن انتشاره قد يتأثر بالتغيرات المناخية إذ قد تؤدي درجات الحرارة المرتفعة إلى إطالة موسم التكاثر لهذا النوع من الذباب. أثبتت المقالة الحالية أن الإصابة في مناطق جنوب العراق أكثر من المناطق الشمالية. قد يكون السبب وراء زيادة انتشار داء اللشمانيا واتساع نطاقه في معظم المحافظات العراقية هو النمو السكاني، التوسع العمراني، الفقر الواضح ونقص الوعي الصحي العام. علاوة على ذلك فإن داء اللشمانيا هو مرض حيواني المنشأ وله عدة مستودعات مثل القوارض، القطط والكلاب مما يشكل عبء على صحة الإنسان. أيضاً فقد شجعت الحروب الهجرة القسرية للعراقيين من محافظاتهم إلى محافظات أخرى مما أدى إلى زيادة معدل الإصابة بهذا الداء في المناطق التي لم تكن فيها الإصابة من قبل. أخيراً فإن داء اللشمانيا منتشر في العراق منذ الخمسينيات ولحد الآن.